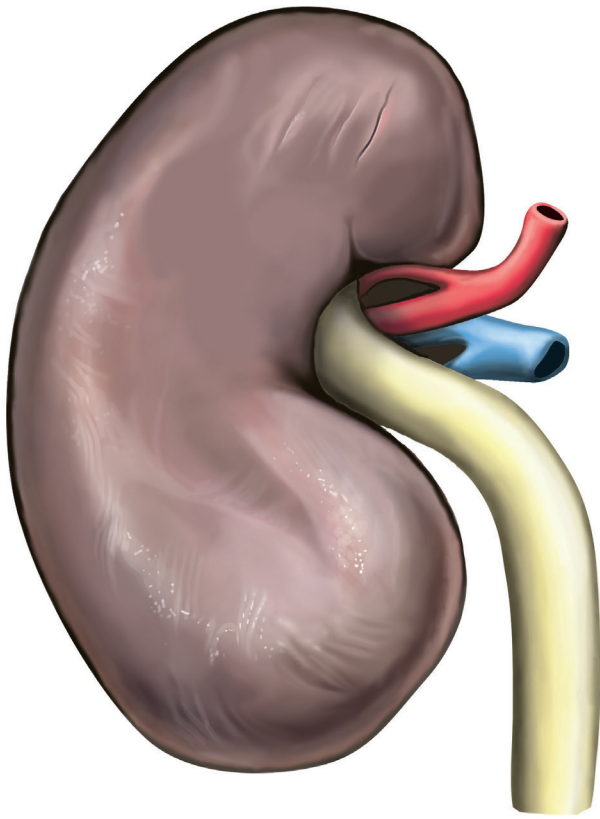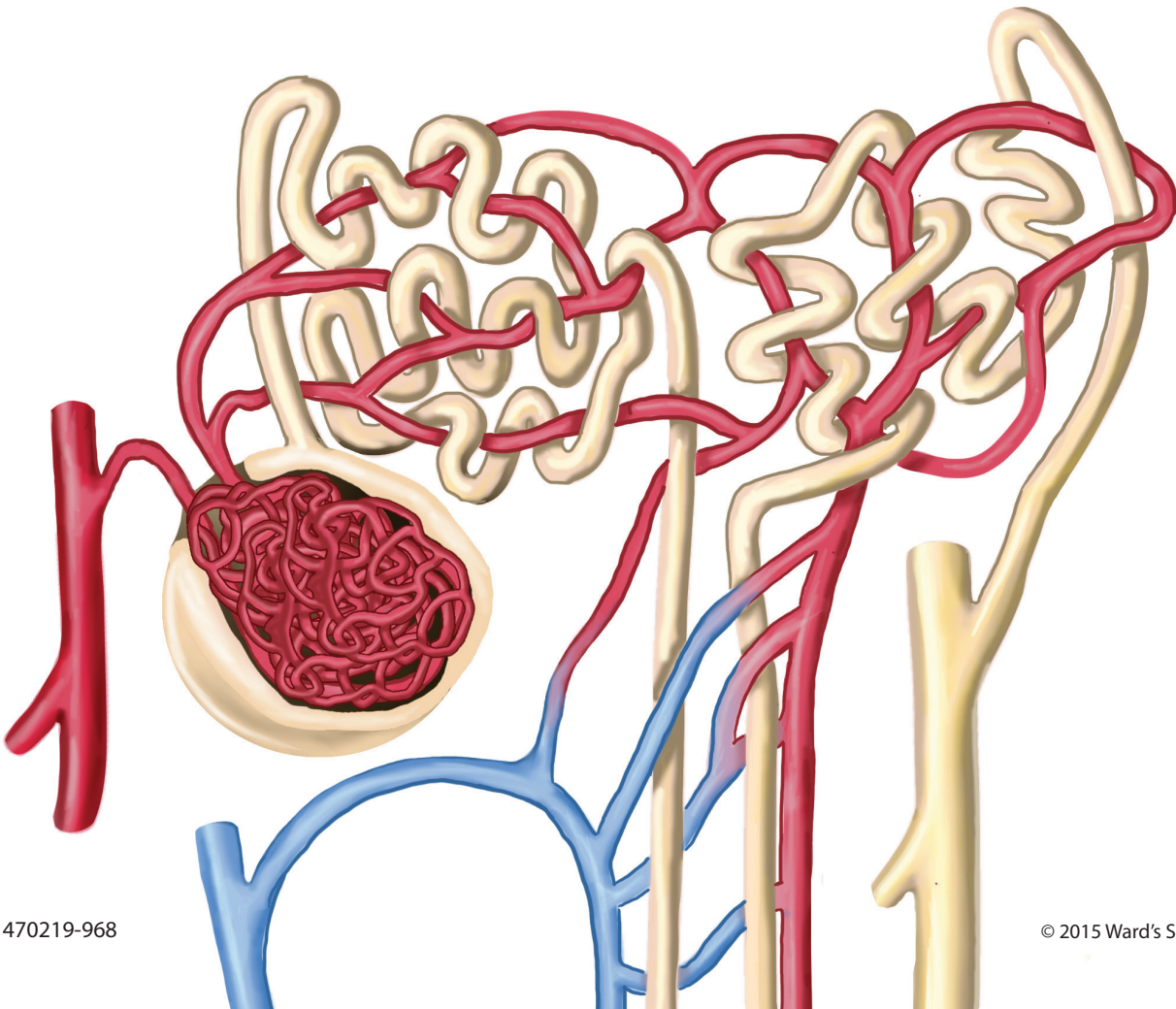


**ward's**  
**science**+

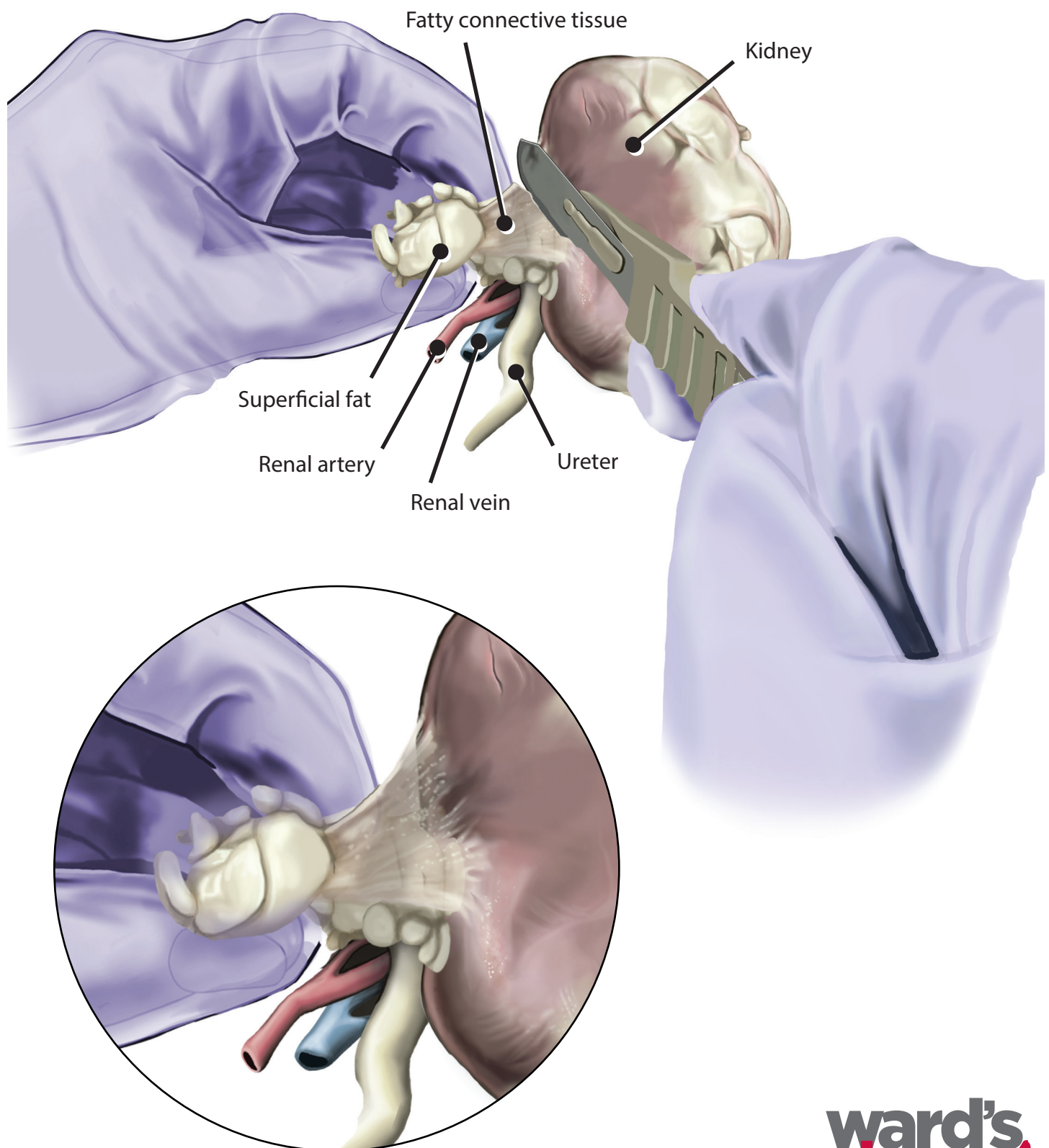
## Mammalian Kidney Dissection Guide

Illustrated by Leah Hofgesang

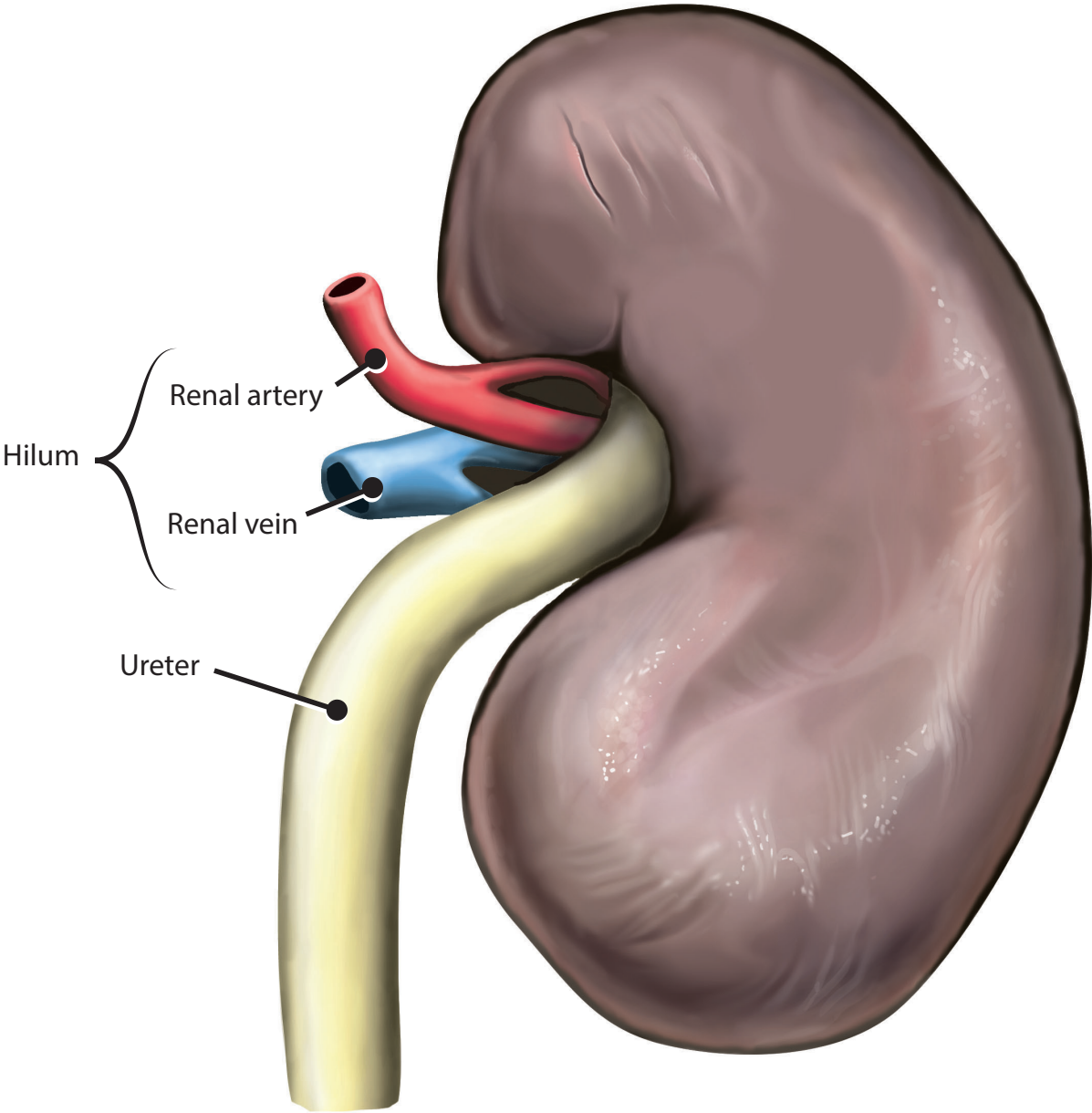




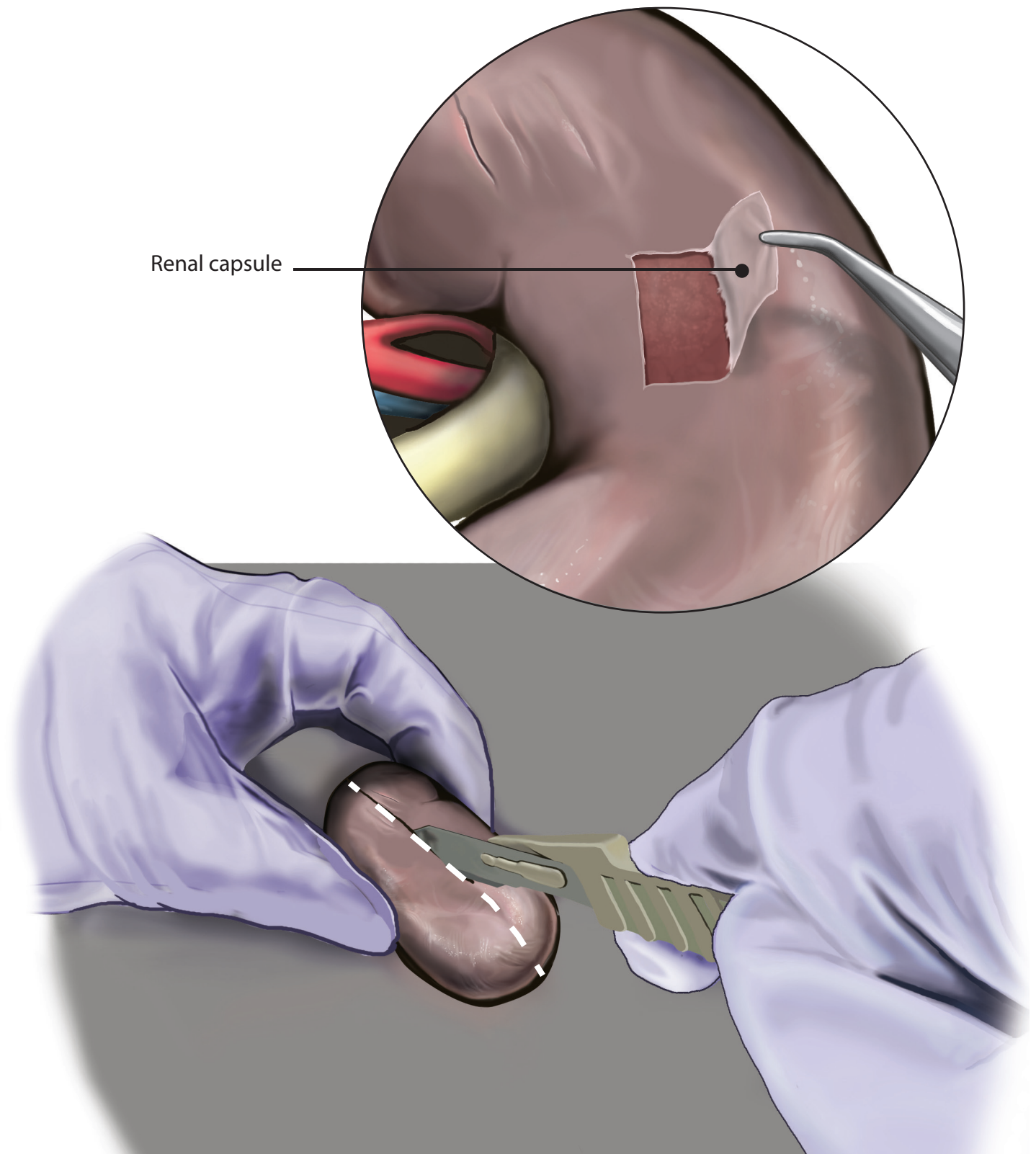
# Clean Fat from the Kidney



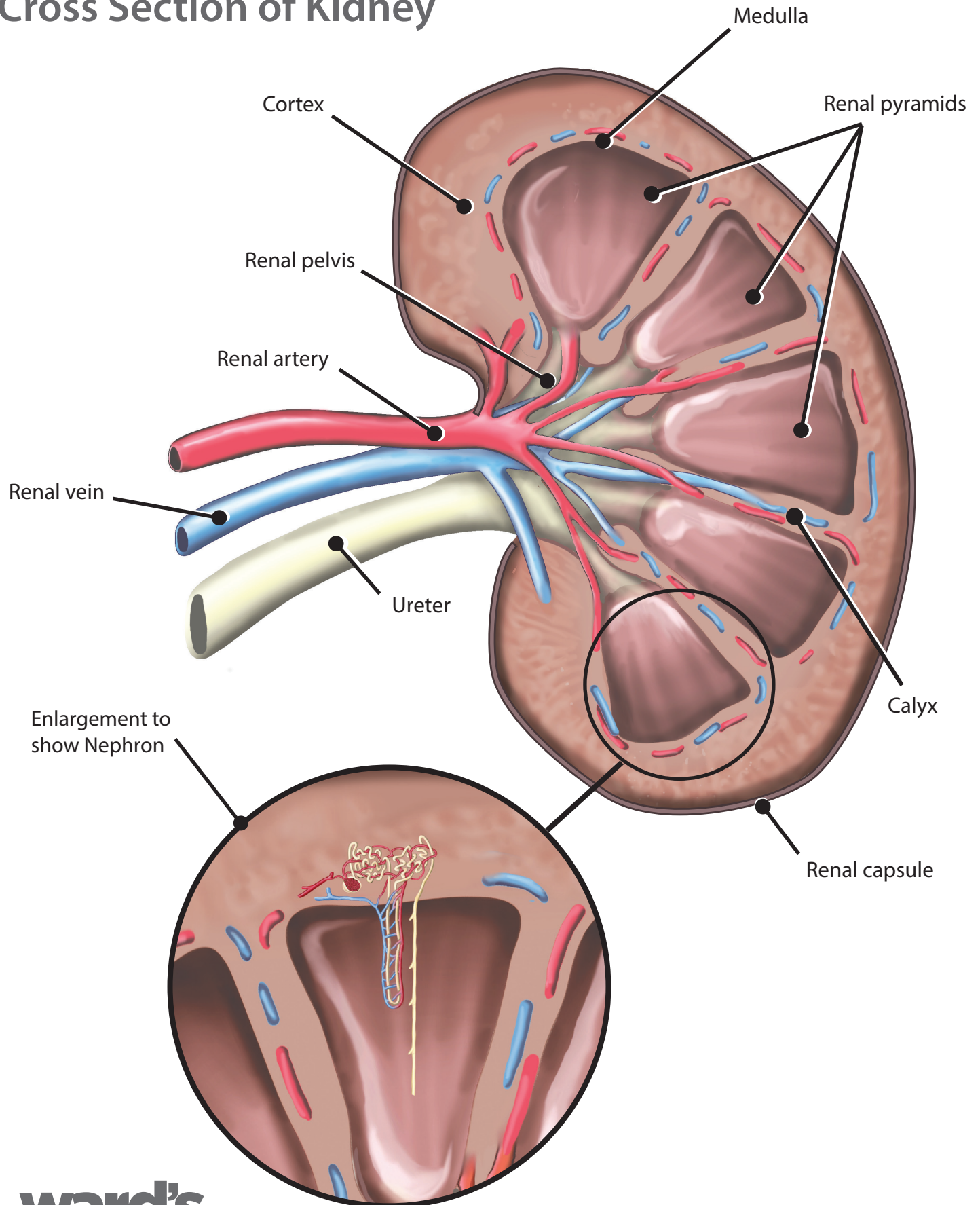
# External Kidney



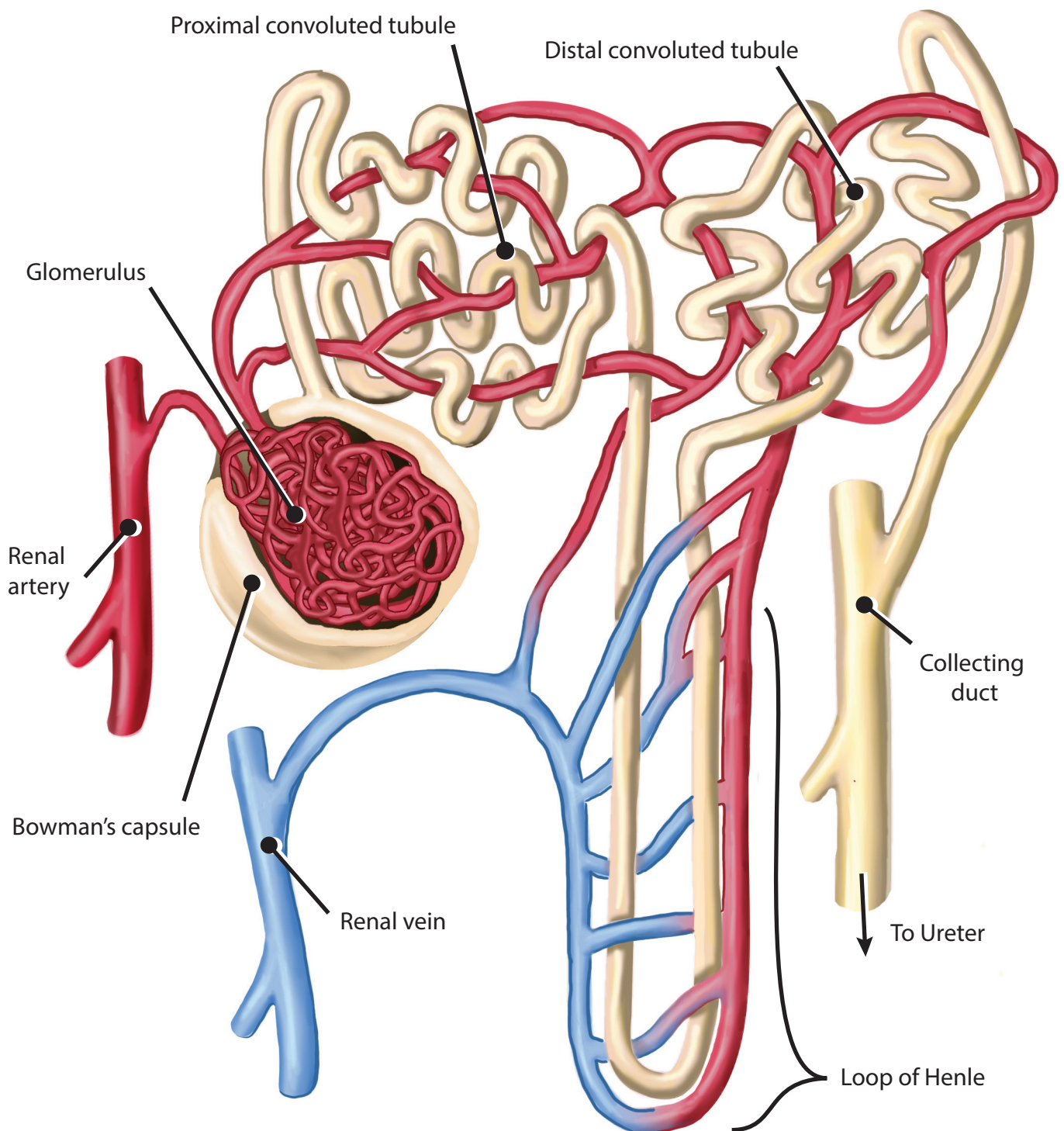
# Kidney Bisection



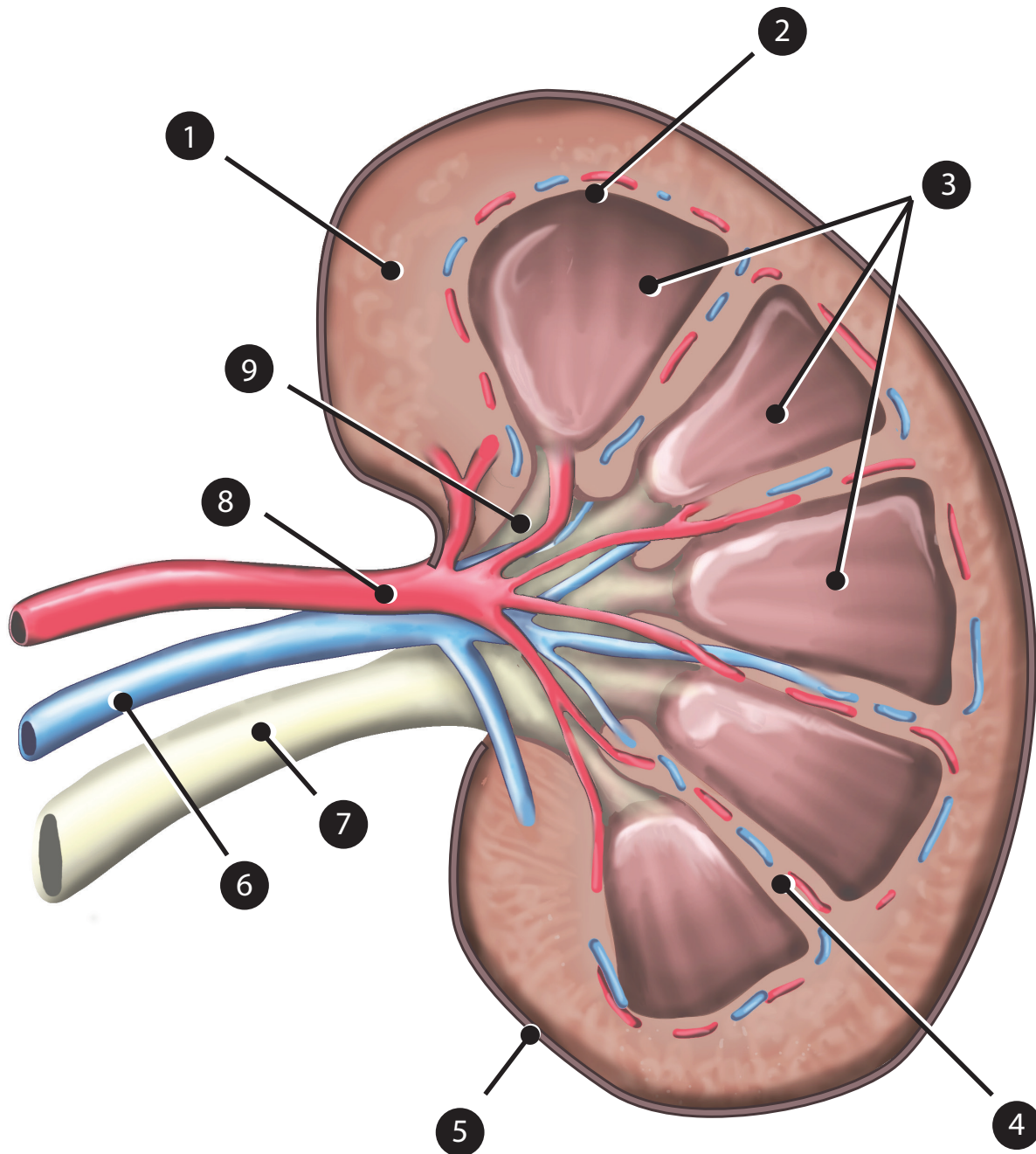
# Cross Section of Kidney



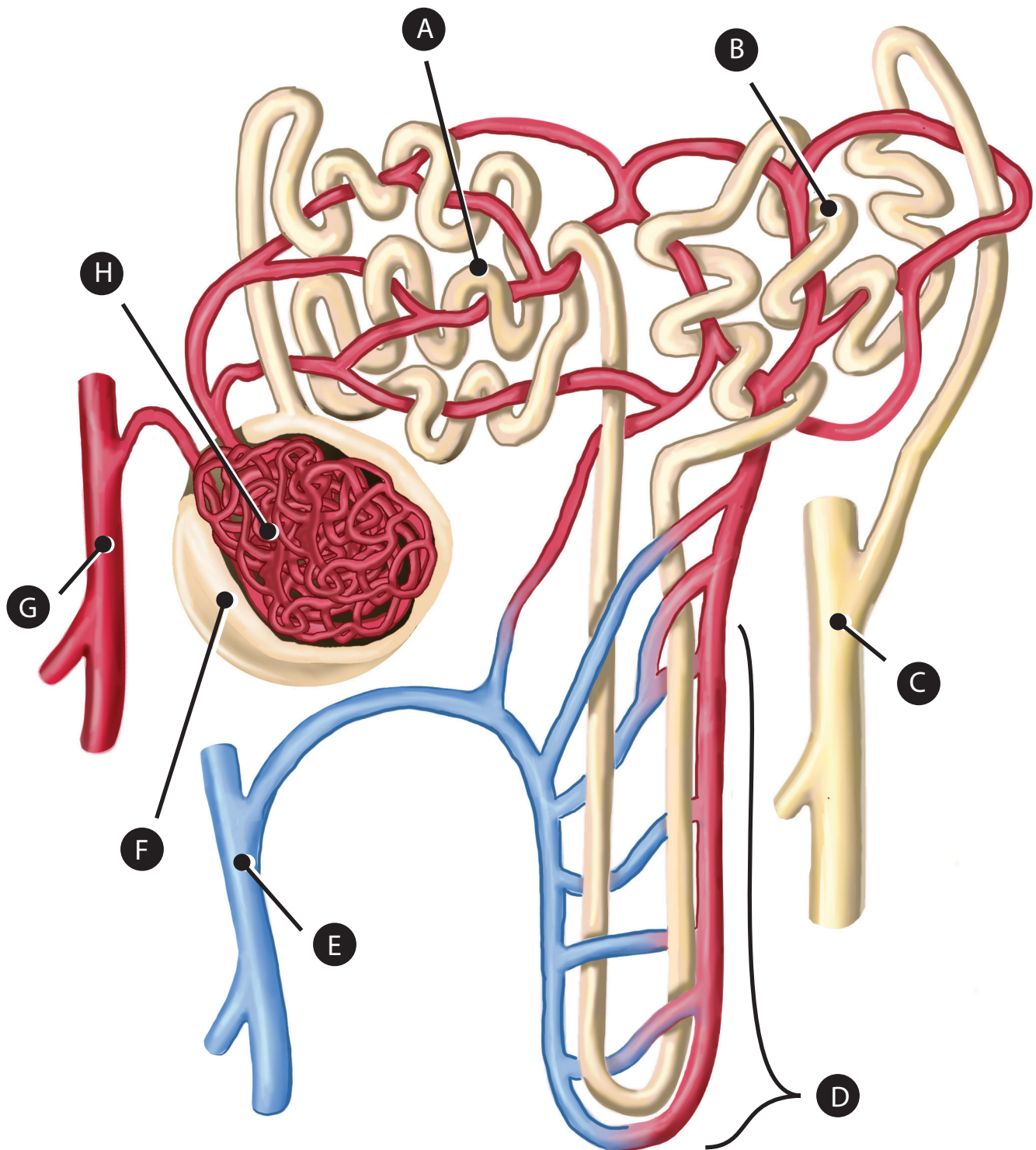
# Nephron



# Kidney Quiz



# Nephron Quiz



# Answers

## Kidney Quiz

1. Cortex
2. Medulla
3. Renal pyramids
4. Calyx
5. Renal capsule
6. Renal vein
7. Ureter
8. Renal artery
9. Renal pelvis

## Nephron Quiz

- A. Proximal convoluted tubule
- B. Distal convoluted tubule
- C. Collecting duct
- D. Loop of Henle
- E. Renal vein
- F. Bowman's capsule
- G. Renal artery
- H. Glomerulus



